

# Expert review on soft-tissue plasmacytomas in multiple myeloma: definition, disease assessment and treatment considerations

Laura Rosiñol,<sup>1</sup> Meral Beksac,<sup>2</sup> Elena Zamagni,<sup>3</sup> Niels W. C. J. Van de Donk,<sup>4</sup> Kenneth C. Anderson,<sup>5</sup> Ashraf Badros,<sup>6</sup> Jo Caers,<sup>7</sup> Michele Cavo,<sup>3</sup> Meletios-Athanasios Dimopoulos,<sup>8</sup> Angela Dispenzieri,<sup>9</sup> Hermann Einsele,<sup>10</sup> Monika Engelhardt,<sup>11</sup> Carlos Fernández de Larrea,<sup>1</sup> Gösta Gahrton,<sup>12</sup> Francesca Gay,<sup>13</sup> Roman Hájek,<sup>14</sup> Vania Hungria,<sup>15</sup> Artur Jurczyszyn,<sup>16</sup> Nicolaus Kröger,<sup>17</sup> Robert A. Kyle,<sup>18</sup> Fernando Leal da Costa,<sup>19</sup> Xavier Leleu,<sup>20</sup> Suzanne Lentzsch,<sup>21</sup> Maria V. Mateos,<sup>22</sup> Giampaolo Merlini,<sup>23</sup> Mohamad Mohty,<sup>24</sup> Philippe Moreau,<sup>25</sup> Leo Rasche,<sup>10</sup> Donna Reece,<sup>26</sup> Orhan Sezer,<sup>27</sup> Pieter Sonneveld,<sup>28</sup> Saad Z. Usmani,<sup>29</sup> Karin Vanderkerken,<sup>30</sup> David H. Vesole,<sup>31</sup> Anders Waage,<sup>32</sup> Sonja Zweegman,<sup>4</sup> Paul G. Richardson<sup>5</sup> and Joan Bladé<sup>1</sup>

<sup>1</sup>Department of Hematology, Hospital Clínic, IDIBAPS, University of Barcelona, Barcelona, Spain, <sup>2</sup>Department of Hematology, Ankara University, Ankara, Turkey, <sup>3</sup>Istituto di Ematologia "Seràgnoli", Dipartimento di Medicina Specialistica Diagnostica e Sperimentale, Università degli Studi, Azienda Ospedaliero-Universitaria di Bologna, Bologna, Italy, <sup>4</sup>Department of Hematology, Amsterdam UMC, VU University, Amsterdam, the Netherlands, <sup>5</sup>Dana Farber Cancer Institute, Harvard Medical School, Boston, MA, <sup>6</sup>University of Maryland at Baltimore, Baltimore, MD, USA, <sup>7</sup>Department of Clinical Hematology, Centre Hospitalier Universitaire de Liège, Liège, Belgium, <sup>8</sup>Hematology and Medical Oncology, Department of Clinical Therapeutics, National and Kapodistrian University of Athens, Alexandra Hospital, Athens, Greece, <sup>9</sup>Division of Hematology, Mayo Clinic, Rochester, MN, USA, <sup>10</sup>Department of Internal Medicine II, University Hospital Würzburg, Würzburg, <sup>11</sup>Interdisciplinary Tumor Center, University of Freiburg, Freiburg, Germany, <sup>12</sup>Department of Medicine, Karolinska Institutet, Huddinge, Stockholm, Sweden, <sup>13</sup>Myeloma Unit, Città della Salute e della Scienza, University of Torino, Torino, Italy, <sup>14</sup>Department of Haematology, University of Ostrava, Ostrava, Czech Republic, <sup>15</sup>Clinica São Germano, São Paulo, Brazil, <sup>16</sup>Medical College Department of Hematology, Jagiellonian University, Krakow, Poland, <sup>17</sup>University Medical Center Hamburg-Eppendorf, Hamburg, Germany, <sup>18</sup>Division of Hematology, Mayo Clinic, Rochester, MN, USA, <sup>19</sup>Instituto Português de Oncologia, Lisboa, Portugal, <sup>20</sup>Poitiers University Hospital, Poitiers, France, <sup>21</sup>Multiple Myeloma and Amyloidosis Service, Columbia University, New York, NY, USA, <sup>22</sup>IBSAL, Cancer Research Center, University Hospital of Salamanca, Salamanca, Spain, <sup>23</sup>Amyloidosis Research and Treatment Center, Department of molecular Medicine, University of Pavia, Fondazione IRCCS Policlinico San Matteo, Pavia, Italy, <sup>24</sup>Department of Clinical Hematology and Cellular Therapy, Hospital Saint-Antoine, Sorbonne University, Paris, <sup>25</sup>Hematology Department, University Hospital Hotel-Dieu, Nantes, France, <sup>26</sup>Princess Margaret Cancer Center, University of Toronto, Toronto, Canada, <sup>27</sup>Berlin, Germany, <sup>28</sup>Erasmus MC Cancer Institute, Erasmus University of Rotterdam, Rotterdam, the Netherlands, <sup>29</sup>Department of Hematologic Oncology and Blood Disorders, Levine Cancer Institute/Atrium Health, Charlotte, NC, USA, <sup>30</sup>Department Hematology and Immunology, Vrije Universiteit Brussel, Brussels, Belgium, <sup>31</sup>John Theurer Cancer, Hackensack Meridian School of Medicine, Hackensack, NJ, USA, and <sup>32</sup>Department of Clinical Molecular Medicine, St. Olavs Hospital, NTNU Trondheim, Trondheim, Norway

## Summary

In this review, two types of soft-tissue involvement in multiple myeloma are defined: (i) extramedullary (EMD) with haematogenous spread involving only soft tissues and (ii) paraskelatal (PS) with tumour masses arising from skeletal lesions. The incidence of EMD and PS plasmacytomas at diagnosis ranges from 1.7% to 4.5% and 7% to 34.4% respectively. EMD disease is often associated with high-risk

cytogenetics, resistance to therapy and worse prognosis than in PS involvement. In patients with PS involvement a proteasome inhibitor-based regimen may be the best option followed by autologous stem cell transplantation (ASCT) in transplant eligible patients. In patients with EMD disease who are not eligible for ASCT, a proteasome inhibitor-based regimen such as lenalidomide-bortezomib-dexamethasone (RVD) may be the best option, while for those eligible for high-dose therapy a myeloma/lymphoma-like regimen such as bortezomib, thalidomide and dexamethasone (VTD)-RVD/cisplatin, doxorubicin, cyclophosphamide and etoposide (PACE) followed by SCT should be considered. In both EMD and PS disease at relapse many strategies have been tried, but this remains a high-unmet need population.

Correspondence: Laura Rosiñol, Department of Hematology, Hospital Clínic, IDIBAPS, University of Barcelona, Barcelona, Spain. E-mail: lrosinol@clinic.cat

**Keywords:** multiple myeloma, plasmacytoma, soft tissue, extramedullary disease, paraskelal plasmacytomas, prognosis, treatment.

Multiple myeloma (MM) represents ~1% of all cancers and 15% of haematological malignancies. The disease is characterised by a proliferation of plasma cells (PCs) with a strong dependence on the bone marrow (BM) microenvironment.<sup>1–3</sup> However, in up to one-third of patients with MM the PC proliferation can escape the cellular microenvironment influences resulting in soft-tissue plasmacytomas, which can constitute the most prominent disease feature.<sup>4–9</sup> Surprisingly, only observational data on plasmacytomas in MM are available and no control studies have been reported to date.

The most frequent mechanism resulting in soft-tissue plasmacytomas is direct growth from skeletal tumours by disrupting the cortical bone<sup>5–8,10–12</sup>, while the remaining result from haematogenous spread with no contact with bony structures.<sup>4,9,13–18</sup> It has been suggested that patients undergoing allogeneic transplantation, as well as those exposed to novel agents, are at higher risk of extramedullary (EMD) progression. However, this has not been proved and there are data supporting the notion that characteristics inherent to the myeloma clone or the host, rather than the type of treatment itself are responsible for soft-tissue myeloma growth. This consensus review, which does not include solitary plasmacytomas recently reviewed,<sup>19</sup> is focussed on: (i) definition, types of growth and incidence of plasmacytomas, (ii) tumour characteristics, (iii) assessment of plasmacytomas and (iv) treatment considerations.

## Definition

The existence of soft-tissue involvement in MM has been known since the very first descriptions of the disease. Early autopsy studies showed extra-skeletal involvement in ~70% of patients with MM.<sup>20–22</sup> In 1969, Pasmantier and Azar<sup>22</sup> reported the findings in 57 consecutive autopsy cases and proposed a classification in three stages according to the presence or absence of macroscopic identifiable tumour outside the bones. Specifically, they proposed Stage I or intra-skeletal involvement when the disease was confined to the BM or the bone; Stage II or paraskelal (PS) disease, when the tumour masses arise directly from bone into immediate PS areas and Stage III or extra-skeletal resulting from metastatic or haematogenous spread. Most patients in Stage I and II had well differentiated PCs (plasmacytic morphology), while in the majority of patients with Stage III the PCs were poorly differentiated (with a plasmablastic appearance). However, the definition of the so-called ‘extramedullary involvement in MM’ has not been uniform. Thus, some authors consider EMD disease only when there is an organ or tissue involvement resulting from haematogenous spread,<sup>13–18</sup> while others also include the soft-tissue involvement originating from bones through direct growth from

skeletal tumours by disrupting cortical bone.<sup>5–8,10–12</sup> In the present expert review, two different types are defined: (i) EMD or extra-osseous, involving only soft tissues, and (ii) PS consisting of soft-tissue masses arising from bone lesions. Of interest, a number of patients develop simultaneously or successively both types of plasmacytomas through the disease course. This fact supports that the myeloma clone is the critical factor for soft-tissue myeloma growth in any given patient.

## Incidence

Data on the incidence of plasmacytomas in MM are only observational. The reported incidence of EMD involvement at diagnosis ranges from 1.7% to 4.5%,<sup>4,9,13,15,17,18</sup> while the rate of PS plasmacytomas ranges from 7% to 34.4%<sup>4–10</sup> (Table I). At relapse, the incidence of EMD disease increases from 3.4% up to 10%,<sup>4,9–11,13,15</sup> while the frequency of PS involvement remains similar to that observed at the time of diagnosis, ranging from 6% to 34.2%<sup>4,5,9,11,12</sup> (Table I). Of interest, when positron emission tomography/computed tomography (PET/CT) imaging is systematically used at the time of diagnosis the reported incidence of EMD disease remains relatively low ranging from 2.4% to 10%.<sup>23–25</sup> It is of interest that in two recent studies, 45% and 56% of patients with plasmacytomas at diagnosis had EMD or PS disease at the time of relapse.<sup>6,26</sup>

It has been suggested that patients undergoing allogeneic transplantation with dose-reduced intensity conditioning (Allo-RIC) have a higher incidence of EMD relapse. Thus, Pérez-Simón *et al.*<sup>27</sup> reported 37% of EMD relapses after Allo-RIC. However, Minnema *et al.*<sup>28</sup> in a series of 54 patients relapsing after Allo-RIC showed a 20.4% incidence of EMD disease (11% in the context of systemic relapse and 9% as localised EMD relapses), defined as the presence of plasmacytomas not originating from skeletal structures. Finally, in a series of 25 patients who relapsed after myeloablative allogeneic transplantation the frequency of EMD relapses was 32%.<sup>29</sup> The reasons for the discrepancy between

**Table I.** Plasmacytomas in multiple myeloma: incidence at diagnosis and at relapse.

	Paraskelal (PS), %*	Extramedullary (EMD), %†
At diagnosis	7–34.4	1.7–4.5
At relapse‡	6–34.2	3.4–10

\*PS: soft-tissue masses arising from vertebrae, ribs, sternum, skull.

†EMD: skin (single or multiple subcutaneous tumours), liver, pleura, breast, lymph nodes and central nervous system (CNS).

‡At relapse >liver, pleura, CNS.

the incidence of plasmacytomas after autologous stem cell transplantation (ASCT)<sup>30,31</sup> and allogeneic transplantation are unclear. Some facts could account for the higher frequency after the allogeneic procedure: (i) younger patients with poor-risk factors and/or clinically aggressive disease, all associated with a higher probability of EMD involvement, are the most likely subset of patients to undergo an allogeneic transplant; (ii) in the above mentioned series, the frequency of plasmacytomas at diagnosis in patients relapsing with EMD disease after allogeneic transplantation was not reported, but presumably it could be high; and (iii) it has been suggested that the graft-*versus*-myeloma (GvM) effect is more effective at the BM level than at EMD sites. All the above could contribute to the higher reported incidence of EMD spread after allogeneic transplantation. Interestingly, in a recent study, treatment with lenalidomide before allogeneic transplantation significantly reduced the risk of post-transplant EMD relapse.<sup>32</sup> Weinstock *et al.*<sup>15</sup> reported an incidence of 8.3% of EMD disease in a series of 663 patients who underwent ASCT at the Dana Farber Cancer Institute (DFCI) from 2005 to 2011. Finally, there is no evidence that the relapse pattern is significantly different in patients exposed to novel agents. Although a recent European Society for Blood and Marrow Transplantation (EBMT) Registry study showed an increase between 2005 and 2015 from 6.5% to 23.7%,<sup>10</sup> the frequency of EMD and PS involvement at our institution has remained constant over the last 45 years.<sup>33</sup>

The use of novel agents has been claimed as a risk factor for the development of EMD disease. However, evidence of such an association is lacking. In fact, only the presence of plasmacytomas at diagnosis was associated with the development of soft-tissue involvement at recurrence after ASCT.<sup>6,26</sup> This supports the notion that the characteristics inherent to the myeloma clone rather than the treatment itself are primarily responsible for EMD spread in MM. Supportive of this, in a recent publication, the DFCI group reported no increase of EMD or PS disease in patients with newly diagnosed myeloma treated with bortezomib/lenalidomide combinations.<sup>12</sup> In the same study, a sensitivity analysis at 5 years of follow-up also showed no significant difference in the rates of EMD progression associated with lenalidomide- or bortezomib-based regimens.<sup>12</sup> However, the data are limited and better control of medullary disease with novel drugs can result in prolongation of survival, which in itself can lead to a higher risk of clonal evolution resulting in plasmacytomas at the time of progression.<sup>34–36</sup>

### Types of plasmacytoma growth and location

Table I summarises the most common locations of soft-tissue plasmacytomas in MM. Local growth resulting in PS involvement is the most common finding and, as already mentioned, consists of soft-tissue masses arising from focal skeletal lesions. The more common locations are vertebrae,

ribs, sternum, skull and pelvis. The haematogenous spread consists of: (i) single or multiple highly vascularised large subcutaneous nodules with a red-purple appearance; (ii) multiple small nodules located at any organ, particularly in skin, liver, breast or kidney; (iii) pleura; (iv) lymph nodes; (v) paramedullary, next to the spine with no demonstrable breakout from bone; and (vi) central nervous system (CNS). In many instances the lactate dehydrogenase (LDH) serum levels are increased in patients with EMD myeloma involvement, so a significant increase in serum LDH is suspicious of EMD disease and constitute the indication for imaging techniques, particularly PET/CT. Skin is the most frequent location at diagnosis, while there is an increased rate of liver, pleura and CNS involvement at relapse.<sup>4,9,13,15</sup> In a retrospective multicentre series of 53 patients with cutaneous involvement there was a predominance of immunoglobulin A (IgA) and light chain myeloma. Of note, there was no correlation between CD56 negativity and skin infiltration. The median survival from skin involvement was only 8.5 months. In addition, patients with IgA myeloma and with plasmablastic morphology had a shorter survival.<sup>36</sup>

The frequency of leptomeningeal involvement is estimated at about 1–2%.<sup>37–42</sup> The dominant clinical picture consists of symptoms from increased intracranial pressure, cranial nerve palsies, paraparesis and/or confusion. Magnetic resonance imaging (MRI) may show leptomeningeal enhancement or meningeal-based lesions resembling intraparenchymatous masses. The cerebrospinal fluid (CSF) typically reveals PCs with plasmablastic morphology and additional EMD involvement is frequently observed. Usually, CNS involvement is seen in advanced phases of the disease along with the involvement of other EMD sites. However, in some instances, leptomeningeal involvement can be the first manifestation of relapse in patients in complete remission (CR). In these cases with a relatively short time between diagnosis and clinical CNS involvement, it is likely that viable myeloma cells were seeded at the CNS sanctuary early in the disease resulting in local relapse, usually followed by systemic myeloma progression. In a multicentre retrospective study with 172 patients with CNS involvement (22% at diagnosis and 78% later in the course of the disease) the median survival from CNS disease was 7 months. At least one previous line of therapy and poor-risk cytogenetic abnormalities by fluorescence *in situ* hybridisation (FISH) were associated with a significantly shorter survival.<sup>42</sup> In a single-institution study including 37 patients with CNS involvement (nine at diagnosis, 28 at relapse) the median overall survival (OS) was 4.6 months, with nine patients surviving for >1 year. All these patients with longer survival underwent CNS radiation therapy and most of them intrathecal chemotherapy and novel agent-based systemic therapy. Patients with CNS involvement at the time of diagnosis had significantly longer OS compared to those at relapse (9.9 vs. 4.1 months).<sup>43</sup>

Plasmacytomas can occasionally be seeded by surgical invasive procedures performed over the course of the disease.

Thus, they can arise from laparotomy scars or catheter insertions and can even precede systemic relapses.<sup>44–46</sup> It is possible that the inflammatory process associated with the tissue injury can facilitate the migration of myeloma cells into the skin to create a reservoir of viable cells eventually able to proliferate.<sup>45</sup> In contrast with this hypothesis, the appearance of an EMD soft-tissue plasmacytoma along the scar from surgery performed 10 years before the diagnosis of MM in a young patient with MM (Fig 1 - PET/CT) has been reported.<sup>47</sup> Extensive EMD involvement resulting from bone surgery or fractures has been reported.<sup>45</sup> In this regard, it is of interest that in the severe combined immunodeficiency (SCID)-human myeloma model, cells from patients with plasmacytomas directly injected to the fetal graft bone proliferate into contiguous soft tissues beyond the bone graft, which is consistent with the clinical behaviour of myeloma cells in patients.<sup>48</sup>

### Tumour characteristics at EMD sites

Plasma cells from EMD disease typically show immature or plasmablastic morphology. In contrast, myeloma cells from PS masses are less undifferentiated and usually show a plasmacytic morphology. Katodritou *et al.*<sup>49</sup> reported that six of seven patients with EMD relapse displayed anaplastic morphology with CD56 negativity at EMD sites. Two patients lost CD56 expression at the EMD location compared with BMPCs. Of interest, it has been reported that CD56 is rarely expressed in plasma cell leukemia (PCL)<sup>50,51</sup> and that CD56 is downregulated in myeloma cells from CNS involvement.<sup>52</sup> In contrast, another study showed no significant differences

in CD56 expression between medullary and EMD myeloma and between intramedullary myeloma and solitary plasmacytoma of bone.<sup>53</sup> More studies are required to establish the role of CD56 in EMD myeloma dissemination. The information on genetic abnormalities in EMD myeloma is limited. It has been suggested that 17p deletion is involved in EMD myeloma progression. Thus 17p deletion was reported in eight of nine patients with MM and CNS involvement.<sup>54</sup> López Anglada *et al.*<sup>55</sup> reported a patient with MM and EMD involvement harbouring t(4;14) in the BM and t(4;14) plus 17p deletion in EMD plasmacytomas. In this regard, one study on paired biopsies from medullary and EMD sites from 12 patients with EMD involvement showed p53 nuclear expression in 75% (nine of 12) of patients at EMD sites *versus* only 8% (one of 12) in the BM samples.<sup>53</sup> However, a limitation of this study is that it was based on immunohistochemistry and not on molecular genetics. Besse *et al.*<sup>56</sup> in another paired sample study, showed that PCs at EMD sites harbour more genetic aberrations than in the BM. In contrast, Katodritou *et al.*<sup>49</sup> reported that four of nine patients with EMD relapse had t(4;14) or t(14;16) in BMPCs at diagnosis with no additional cytogenetic changes at EMD sites. In two reports from Billecke *et al.*<sup>57,58</sup> EMD and soft-tissue plasmacytomas arising from skeletal lesions showed a similar incidence of deletion 17p ranging from 21% to 32%. Of note, in these studies the frequency of deletion 17p was higher than the usually reported from BMPCs or from osteolytic lesions.<sup>57,58</sup> In one of the above series, three patients had deletion 17p at EMD sites and not in the BM, suggesting a role of deletion 17p in EMD myeloma progression. For a meaningful interpretation of these results the study of the

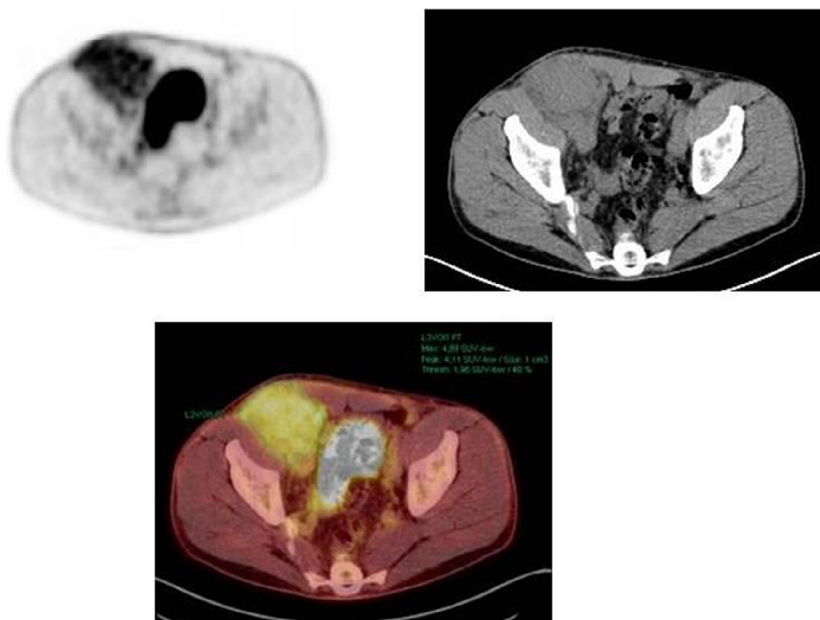


Fig 1. Extramedullary plasmacytoma arising along the scar of a previous surgery (positron emission tomography/computed tomography). With permission from the *Archives of Clinical and Biomedical Research*.

clonal signature to confirm or deny that the same clone is present in all involved sites would be required. A higher incidence of t(4;14) in haematogenous spread *versus* PS plasmacytomas (37% vs. 18%) has been reported.<sup>58</sup> Deng et al<sup>59</sup> reported that patients with EMD disease had a higher prevalence of p53 deletion at FISH analysis (34.5% vs. 11.9%) and significantly greater LDH levels compared with those without EMD disease. Rasche et al<sup>60</sup> reported that 10 of 19 (52%) patients who relapsed with prominent haematogenous EMD involvement had high-risk cytogenetics at the time of relapse. In a large Spanish transplantation trial, the proportion of patients with high-risk cytogenetics was similar in patients with and without PS involvement (24% vs. 21%).<sup>61</sup> Therefore, the genetic abnormalities harboured by BMPCs are not associated 'per se' with soft-tissue involvement. However, the Arkansas group performed molecular gene expression profiling (GEP) studies on BMPCs and found that haematogenous EMD disease was associated with high-risk features, particularly *MAFB* gene overexpression and markers of highly proliferative disease.<sup>13</sup> The cumulative incidence of EMD disease was significantly increased in patients with GEP-defined high-risk disease at baseline and with baseline cytogenetic abnormalities. They concluded that the haematogenous EMD spread was more prevalent in genomically defined high-risk myeloma.<sup>13</sup> This could help to identify EMD-unique genes that might be targeted by new drugs or different treatment approaches. Finally, *MYC* overexpression and a higher proliferation rate leading to a more aggressive behaviour have been reported in PCs from EMD sites.<sup>54,59,60</sup>

## Assessment of soft-tissue involvement in multiple myeloma

### Assessment of plasmacytomas

In some patients plasmacytomas can be assessed by physical examination (e.g. a palpable mass). However, in most instances radiographic imaging techniques are needed.<sup>62,63</sup> MRI is useful in the assessment of both the nature (EMD *versus* PS) and the extent of soft-tissue disease, particularly when evaluating the spine.<sup>64</sup> Thus, MRI is mandatory in patients with suspicion of spinal cord or nerve root compression in order to accurately assess the level and extent of the lesions and the degree of epidural space involvement.<sup>64</sup> MRI is also mandatory when CNS involvement is suspected, as well as CSF studies looking for a monoclonal (M)-protein and PCs. The typical findings are leptomeningeal enhancement and/or meningeal-based lesions resembling intraparenchymatous masses.<sup>64</sup> Fluorodeoxyglucose (FDG)-PET/CT is the most useful whole body technique in patients in whom soft-tissue involvement is suspected.<sup>65-67</sup> In a recent systematic review, its sensitivity and specificity were 96% and 78% respectively.<sup>68</sup> Thus, PET/CT is the whole body imaging technique of choice to detect EMD or PS involvement in MM. The main limitation of PET/CT has been the non-

standardisation of visual criteria and the possible lack of interobserver reproducibility.<sup>69,70</sup> Hopefully, the recent work on standardisation of <sup>18</sup>F-FDG PET/CT according to the Deauville criteria, based on the joint analysis of two prospective randomised Phase III trials, will be helpful.<sup>71</sup> Along with the metabolic uptake [standardised uptake value (SUV)] it is important to carefully look at: (i) the findings of the companion CT (co-localisation), (ii) the nature of soft-tissue components (i.e. EMD *versus* soft-tissue masses arising from bones), (iii) high-risk areas of cord compression or skull-base invasion and (iv) potential false positive findings, particularly healing bone fractures, stress fractures or bone infarcts of the femoral head, as well as degenerative/arthritis processes resembling soft-tissue involvement with high metabolic uptake. In conclusion, a PET/CT should be done in patients in whom soft-tissue myeloma involvement is suspected based on clinical symptoms or considered at high-risk (i.e. patients with high LDH), as well as at the time of biochemical relapse in patients with a previous history of plasmacytomas, given the high frequency of soft-tissue involvement at relapse in this population.

### Assessment of response to therapy

The uniform response criteria by the International Myeloma Working Group (IMWG) requires the disappearance of soft-tissue masses for a CR and a decrease  $\geq 50\%$  for partial remission (PR).<sup>72</sup> However, there is no specification on the required decrease of plasmacytomas to declare very good PR (VGPR). As the serum and urine paraprotein requirements for VGPR are very stringent (i.e. serum M-protein decrease  $\geq 90\%$  and urine light chain protein excretion  $< 100$  mg/24 h), we recommend that for VGPR assignment evidence of active plasmacytoma must have disappeared on physical examination and/or imaging techniques.<sup>73</sup> Conversely, there is no recommendation by the IMWG on the required frequency of plasmacytomas assessment. We believe that clinical assessment (i.e. measurement of a palpable soft-tissue mass) should be performed at the beginning of each treatment cycle, while the assessment of plasmacytomas identified by imaging techniques, ideally by PET/CT (considering size and metabolic uptake) and/or MRI, should be done at 3 months after the initiation and subsequently at the physician's discretion if there is still persistent active disease. If after 3 months of therapy there is still active disease, the continuation of the same therapy, the administration of radiation therapy or a switch to an alternative treatment should be considered depending on the degree of paraprotein and plasmacytoma response. In case that the plasmacytoma decrease is  $< 50\%$ , local radiation and/or switch of systemic therapy should be considered, while with a decrease of  $\geq 50\%$  in the plasmacytoma size (PR or better) the continuation of the same therapy is recommended. If the plasmacytoma has disappeared and if there is no evidence of active disease at a potential residual site (i.e. CR)<sup>72</sup> it would be reasonable to perform

yearly imaging as part of follow-up and at any time if plasmacytoma recurrence is suspected or if progressive disease occurs as defined by an increase in the M-protein or clinical deterioration. Progression is defined as the recurrence of a known plasmacytoma that had disappeared with therapy, the appearance of any new area of soft-tissue involvement or the increase in  $\geq 25\%$  of existing lesions.<sup>72</sup> Concerning the follow-up of plasmacytoma, it is important to consider that some lesions can be differently perceived with different imaging techniques or variously interpreted by different radiologists. Ideally, the same reader with the use of the same imaging technique should report the baseline and follow-up assessments for a particular patient in order to minimise both the inter-technique and the inter-reader variability.<sup>73</sup>

## Prognosis

Using a time-dependant statistical analysis, Varettoni *et al.*<sup>6</sup> showed that the presence of soft-tissue involvement at any time during the course of the disease was associated with significantly shorter progression-free survival (PFS) and OS. Wu *et al.*<sup>5</sup> reported that the presence of plasmacytomas was associated with poorer prognosis in patients treated with conventional chemotherapy. However, in the above two studies, patients who received ASCT had similar outcome, irrespective of the presence or absence of plasmacytomas, suggesting that high-dose melphalan may overcome the negative impact of soft-tissue involvement in this setting. A report from South Korea showed similar results.<sup>74</sup> In a recent EBMT Registry study, patients with PS involvement who received up-front ASCT had similar PFS and OS as those with no plasmacytomas.<sup>10</sup> In contrast, patients with EMD had significantly shorter PFS rates at 3 years after ASCT than those with PS involvement or those without plasmacytomas and also significantly worse OS rates.<sup>10</sup> In this study, tandem ASCT did not improve the outcome of patients with plasmacytomas, neither with PS nor with EMD disease. In contrast, in a Programa Español para el tratamiento de las Hemopatías Malignas (PETHEMA) transplantation trial there were no significant differences in PFS between patients with or without PS involvement; however, the OS was significantly shorter in those with plasmacytomas.<sup>61</sup> Finally, in a meta-analysis of eight recent Italian trials using new drugs the detrimental effect of EMD disease at diagnosis was limited.<sup>75</sup> Of note, in all the four above mentioned studies, the vast majority of patients had PS involvement and very few had EMD disease. Importantly, in the era of novel agents, Usmani *et al.*<sup>13</sup> reported that EMD spread was associated with a significantly poorer PFS and OS, regardless of whether patients were treated according to 'Total Therapy' protocols involving intensive chemotherapy. In other studies in which PET/CT was systematically performed at the time of up-front therapy initiation, the presence of EMD disease was associated with a significantly shorter PFS and OS, despite the incidence being only between 6% and 10%.<sup>22–25</sup> Pour *et al.*<sup>11</sup>

reported in the relapsed setting that patients with soft-tissue involvement had poorer prognosis than those relapsing with no plasmacytoma. Importantly, the survival of those with EMD disease was significantly shorter when compared with that of patients with PS masses. Similar results have been reported by others.<sup>76,77</sup> In our own series, the median survival of 29 patients with EMD disease at diagnosis was significantly shorter than that of 191 patients with PS plasmacytomas (1.8 vs. 3.5 years).<sup>33</sup> A multicentre study of 127 patients with EMD disease also showed dismal outcome.<sup>78</sup> The prognosis is particularly poor in patients with CNS involvement who have a median survival of  $< 3$  months,<sup>38,39</sup> and even when novel agents are used outcomes to date have been dismal.<sup>41,79,80</sup> Survival may be improved by the combination of radiation therapy (cranial or craniospinal) along with systemic plus intrathecal therapy, but this constitutes an area of exquisite unmet medical need.<sup>17,37</sup>

## Treatment approach

### General considerations

As outlined above, the outcome of patients with EMD involvement is worse than those with PS disease. This could be a consequence of intrinsically more aggressive disease and/or different drug sensitivity. Unfortunately, most of the published series include both types of plasmacytomas under the term 'extramedullary disease' and definitive conclusions cannot be drawn. However, some considerations can be made. First, alkylating agents are effective as front-line therapy, particularly high-dose melphalan, for PS involvement. In this regard, Varettoni *et al.*<sup>6</sup> reported that 72% of patients with soft-tissue involvement at the time of diagnosis achieved at least a PR. Similarly, Wu *et al.*<sup>5</sup> found that in patients who received initial conventional therapy the PR rate was 52% and 50%, irrespective of the presence or absence of plasmacytomas. The response rate was also similar at 90% versus 91% in patients who received high-dose therapy intensification. On the other hand, the results of an EBMT Registry study showed that patients with PS plasmacytomas who underwent ASCT had similar survival outcomes as those without soft-tissue myeloma involvement.<sup>10</sup> Second, the data concerning the efficacy of newer agents are limited. Bortezomib seems to be of benefit in patients with PS disease with less evidence for EMD involvement.<sup>81–83</sup> Carfilzomib showed limited efficacy in relapsed patients with MM and plasmacytomas, particularly in those with EMD disease.<sup>84,85</sup> The efficacy of ixazomib is unknown. In contrast, marizomib, which is able to cross the blood–brain barrier, has shown efficacy in CNS involvement,<sup>86</sup> an observation initially recognised by the results of a Phase I study in  $> 60$  patients with relapsed/refractory MM (RRMM).<sup>87</sup> The efficacy of immunomodulatory drugs (IMiDs) in this context is also limited. In a single-institution series, none of the 11 patients with

plasmacytomas (seven patients with PS involvement and four with EMD disease) responded to single-agent thalidomide.<sup>88</sup> The failure of soft-tissue involvement to respond to thalidomide has also been reported by others.<sup>89–92</sup> There are no published data on the efficacy of lenalidomide on plasmacytomas in the relapse setting. Concerning pomalidomide plus low-dose dexamethasone, the Mayo Clinic group reported that four of 13 patients (31%) with EMD disease responded with two CRs and two PRs.<sup>14</sup> In contrast, the Catalan Myeloma Group only observed two responses (one CR and one PR) amongst 21 patients with RRMM treated with pomalidomide and dexamethasone.<sup>93</sup> Third, a dissociation between paraprotein ('medullary') and soft-tissue response has been observed. Also, progression of plasmacytomas despite good BM and serological response in patients receiving thalidomide has been reported.<sup>88–90,92</sup> These phenomena have also been observed with bortezomib<sup>83</sup> and carfilzomib.<sup>85</sup>

Fourth, concerning more novel drugs, there are very limited data on the efficacy of daratumumab, with one study showing an overall response rate (ORR) of 17% in CD38 monoclonal antibody (MoAb)-naïve patients.<sup>94</sup> A recent single institution report showed very modest efficacy of single-agent daratumumab in advanced patients with relapsed myeloma, including EMD disease.<sup>95</sup> Isatuximab associated with pomalidomide and dexamethasone (Isa-Pd) resulted in 50% ORR (seven of 14) compared with only 10% (one of 10) with pomalidomide and dexamethasone (Pd) in patients with RRMM and soft-tissue plasmacytomas. Also, the PFS was also longer with Isa-Pd compared with Pd (4.57 vs. 1.56 months).<sup>96</sup> Of interest, melflufen has resulted in a significant response rate in both EMD and PS disease,<sup>97</sup> with an overall response (PR or better) of 23% (13/55 patients) and similar duration of response between patients with or without plasmacytomas.<sup>97</sup> Selinexor and dexamethasone showed a response rate of 31% (five of 16). However, in this study only 16 out of 27 patients with plasmacytomas were available for response evaluation.<sup>98</sup> Venetoclax could be considered for relapsed patients with soft-tissue involvement and with t (11;14), but there are no reported data.

It must be noted that the small sample size and the absence of controlled trials are important shortcomings in

the assessment of the efficacy of anti-myeloma therapy on soft-tissue involvement in MM and consequently it is difficult to recommend specific treatment approaches.

#### *Up-front therapy for patients with PS plasmacytomas*

Considering that cytotoxic agents and in particular alkylating drugs, as well as bortezomib, are the most active agents in patients with PS plasmacytomas, the treatment of choice for patients not immediately proceeding to ASCT may be the combination of bortezomib with melphalan, prednisone and daratumumab (Dara-VMP)<sup>99</sup> or lenalidomide bortezomib and dexamethasone (RVD).<sup>100</sup> Assuming that high-dose melphalan can overcome the poor prognosis of PS involvement and that a proteasome inhibitor-based regimen, particularly bortezomib, thalidomide and dexamethasone (VTD) or RVD likely with a MoAb, such as daratumumab, constitutes the best preparative induction regimen; the best option for patients eligible for ASCT should be an induction proteasome inhibitor-based regimen followed by high-dose melphalan/autologous stem cell support<sup>74,101</sup> (Table II). It seems that tandem ASCT is of no additional benefit.<sup>10</sup> Local radiation therapy should be urgently administered in cases of spinal cord compression and also considered in patients with severe compressive pain, in those with bulky plasmacytomas, as well as in patients with persistent local disease after systemic therapy. Unfortunately, there is a lack of prospective clinical trials on patients with MM presenting with plasmacytomas. Recently, the Gruppo Italiano Malattie EMatologiche dell'Adulto (GIMEMA) group published the outcome of 267 patients with soft-tissue involvement (243 PS) included in eight prospective trials, using bortezomib, lenalidomide or carfilzomib compared with 2065 patients without plasmacytomas.<sup>75</sup> The median PFS was similar in both groups (25.3 vs. 25.2 months), while the median OS was significantly shorter in patients with soft-tissue involvement (63.5 vs. 79.9 months). The authors conclude that in patients treated with new drugs the detrimental effect of PS involvement at diagnosis is limited and that both proteasome inhibitors and lenalidomide are effective in this situation.<sup>75</sup>

**Table II.** Front-line therapy.

	Paraskeletal (PS)	Extramedullary (EMD)
Elderly	MPV/daratumumab RVD ± daratumumab CyborD ± daratumumab	MPV/daratumumab RVD ± daratumumab CyBorD ± daratumumab
HDT-eligible	Bortezomib-based regimen (VTD, PAD, RVD) ± daratumumab+ASCT*	VTD or RVD-PACE → allo-SCT VTD or RVD-PACE → tandem ASCT-allo-RIC

Allo-RIC, allogeneic transplantation with dose-reduced intensity conditioning; ASCT, autologous stem cell transplantation; CyBorD, bortezomib, cyclophosphamide and dexamethasone; D, dexamethasone; M, melphalan; P, prednisone; PACE, cisplatin, doxorubicin, cyclophosphamide and etoposide; PAD, bortezomib, doxorubicin, high-dose dexamethasone; R, lenalidomide; T, thalidomide; V, bortezomib.

\*ASCT may overcome the poor prognosis of PS plasmacytoma.

*Up-front therapy for EMD disease*

Patients with overt haematogenous myeloma spread should be considered as having an ultra-high-risk disease with an extremely poor outcome, as current treatment approaches are unsatisfactory. However, until more effective options are available, the VMP or RVD regimens seem to be the treatment of choice for patients who are not eligible for ASCT.<sup>100,102</sup> Considering that daratumumab improves the efficacy of VMP and also RVD, the addition of a CD38-targeting MoAb would be most reasonable. For transplant-eligible patients, a combined intensive anti-myeloma/anti-lymphoma regimen such as VTD or VRD/cisplatin, doxorubicin, cyclophosphamide and etoposide (PACE)<sup>103</sup> followed by a tandem ASCT or ASCT followed by Allo-RIC seems theoretically an alternative option<sup>104</sup> (Table II). Although these patients usually respond to induction therapy, early relapse is very common.<sup>105</sup> For this reason, a suggested approach could be an intensive short induction (such as two or three cycles of VTD or VRD-PACE) immediately followed by the high-dose approach if appropriate. In case of tandem transplantation, the interval between the first and second procedure should also be as short as possible in order to avoid disease progression while waiting for the allogeneic procedure, but this may be challenging. In patients with high-risk cytogenetics tandem ASCT seems to be of benefit.<sup>106</sup> However, the EBMT Registry has recently reported no benefit of tandem ASCT over single ASCT in patients with EMD disease,<sup>10</sup> further emphasising the need for new approaches. In this regard, the European Myeloma Network (EMN) is conducting a Phase II trial of daratumumab combined with bortezomib, cyclophosphamide and dexamethasone in patients with MM and EMD disease at diagnosis and first relapse (EMN19 study, NCT 04166565).

*Treatment at relapse*

The prognosis of patients relapsing with soft-tissue involvement either EMD or PS is extremely poor.<sup>4,9,11–18,59</sup> Given the fact that currently many patients have already received bortezomib-based front-line regimens frequently with IMiDs, the most effective treatment at relapse consists of lymphoma-like regimens such as PACE, dexamethasone, cyclophosphamide, etoposide, and cisplatin (DCEP) or dexamethasone, carmustine, etoposide, doxorubicin, melphalan (Dexa-BEAM)<sup>105–107</sup> (Table III). The response rate is ~50%, but the duration of response is short, lasting for a median of only 4 months.<sup>108,109</sup> In patients who are eligible for SCT an appropriate approach would be the administration of two or three chemotherapy cycles followed by a high-dose procedure, provided that the patient is in response at the time of transplant, as there appears to be no meaningful role for ASCT in patients with resistant disease and the utility of allo-SCT may also be very limited. In patients relapsing after a durable response to bortezomib, proteasome inhibition-

Table III. Treatment at relapse.

Lymphoma-like regimen*
PACE
DT-PACE
DCEP
Dexa-BEAM
HDT/SCT
Novel agent combinations (e.g. carfilzomib-based combinations – such as KPD, KCyD, others - PVD, selinexor-based combinations, isatuximab-based combinations)
Immunotherapy: CAR-T cell therapy, bi-specific antibodies (BiTEs)

CAR, chimeric antigen receptor; DCEP, dexamethasone, cyclophosphamide, etoposide and cisplatin; Dexa-BEAM, dexamethasone, carmustine, cytarabine, etoposide and melphalan; HDT, high-dose therapy; KCyD, carfilzomib, cyclophosphamide and dexamethasone; KPD, carfilzomib, pomalidomide and dexamethasone; (DT-)PACE, (dexamethasone, thalidomide-) cisplatin, doxorubicin, cyclophosphamide and etoposide; PVD, pomalidomide, bortezomib and dexamethasone; SCT, stem cell transplantation.

\*Short response duration.

based therapy could also be an option. Alternatively, in patients initially treated with IMiD-based therapy, rescue with proteasome inhibitor-based regimens may be effective. The initial results with melflufen are encouraging and melflufen-based regimens could be of help.<sup>97</sup> For patients with CNS involvement craniospinal radiation, triple intrathecal chemotherapy (glucocorticoids, methotrexate and cytarabine) and systemic IMiD-based therapy is recommended.<sup>43</sup> With the limitations of most standard approaches in the control of EMD disease, newer immunotherapeutic strategies such as toxin immunoconjugate MoAbs, bi-specific antibodies against CD3 and B-cell maturation antigen (BCMA) recruiting endogenous T cells and autologous chimeric antigen receptor (CAR) T cells, mainly directed against BCMA present on the malignant PC surface are promising.<sup>110</sup> Belantamab mafadotin, a MoAb against BCMA conjugated with monomethyl auristatin F (MMAF), have shown only limited efficacy.<sup>111</sup> Some rapid and deep responses have been reported after CAR-T cell treatment with disappearance of extensive EMD disease including cord compression, extraosseous plasmacytoma and pleural involvement in one patient or the disappearance of a large abdominal mass on CT after CAR-T cell infusion in another patient.<sup>112,113</sup> In two recent publications where EMD disease was prevalent (27% and 28% respectively),<sup>114,115</sup> good quality responses have been reported. Thus, in one of the studies, eight of the nine patients with EMD disease responded to CAR-T, including four CRs and two VGPRs.<sup>115</sup> However, there are some shortcomings: (i) short follow-up in the majority of trials, (ii) scarce information in the clinical trials on the response and PFS of patients with EMD disease in studies evaluating CAR-T cell or bi-specific antibodies, and (iii) the specific response in PS or haematogenous spread plasmacytoma is not fully described



## Acknowledgement

This work has been supported in part by grant PI12/01093 from Instituto de Salud Carlos III.

## Author Contributions

Laura Rosiñol and Joan Bladé wrote the first drafts, which circulated three times among all the authors who made comments. All the authors approved the final version of the manuscript.

## References

- Mitsiades CS, McMillin DW, Kippel S, Hideshima T, Chauhan D, Richardson PG, et al. The role of bone marrow microenvironment in the pathophysiology of myeloma and its significance in the development of more effective therapies. *Hematol Oncol Clin North Am.* 2007;**21**:1007–34.
- Vande Broek I, Vanderkerken K, Van Camp B, Van Riet I. Extravasation and homing mechanisms in multiple myeloma. *Clin Exp Metastasis.* 2008;**25**:325–34.
- Ghobrial I. Myeloma as a model for the process of metastasis: implications for therapy. *Blood.* 2012;**120**:20–30.
- Bladé J, Fernández de Larrea C, Rosiñol L, Cibeira MT, Jiménez R, Powles R. Soft-tissue plasmacytomas in multiple myeloma: incidence, mechanisms of extramedullary spread, and treatment approach. *J Clin Oncol.* 2011;**29**:3805–12.
- Wu P, Davies F, Boyd K, Thomas K, Dines S, Saso RM, et al. The impact of extramedullary disease at presentation in the outcome of myeloma. *Leuk Lymphoma.* 2009;**50**:230–5.
- Varettoni M, Corso A, Pica G, Mangiacavalli S, Pascutto C, Lazzarino M. Incidence, presenting features and outcome of extramedullary disease in multiple myeloma: a longitudinal study on 1,003 consecutive patients. *Ann Oncol.* 2009;**21**:325–30.
- Bladé J, Lust J, Kyle RA. Immunoglobulin D multiple myeloma: presenting features response to therapy, and survival in a series of 53 cases. *J Clin Oncol.* 1994;**12**:2398–404.
- Bladé J, Kyle RA, Greipp PR. Presenting features and prognosis in 72 patients with multiple myeloma who were younger than 40 years. *Br J Haematol.* 1996;**93**:345–51.
- Buthani M, Foureau DM, Atrash S, Voorhees PM, Usmani SZ. Extramedullary multiple myeloma. *Leukemia.* 2020;**34**:1–20.
- Gagelmann N, Eikema DJ, Iacobellis S, Koster L, Nahi H, Stoppa AM, et al. Impact of extramedullary disease in patients with newly diagnosed multiple myeloma undergoing autologous stem cell transplantation: a study from the Chronic Malignancies Working Party of the EBMT. *Haematologica.* 2018;**103**:890–7.
- Pour L, Sevcikova S, Greslikova H, Kupka R, Majkova P, Zahradova L, et al. Soft-tissue extramedullary multiple myeloma prognosis is significantly worse in comparison to bone-related extramedullary relapse. *Haematologica.* 2014;**99**:360–4.
- Varga C, Xie W, Laubach J, Ghobrial IM, O'Donnell EK, Weinstock M, et al. Development of extramedullary myeloma in the era of novel agents: no evidence of increased risk with lenalidomide-bortezomib combinations. *Br J Haematol.* 2015;**169**:843–50.
- Usmani SZ, Heuck C, Mitchell A, Szymonifka J, Nair B, Hoering A, et al. Extramedullary disease portends poor prognosis in multiple myeloma and is overrepresented in high-risk disease even in the era of novel agents. *Haematologica.* 2012;**97**:4761–7.
- Short KD, Rajkumar SV, Larson D, Buadi F, Hayman S, Dispenzieri A, et al. Incidence of extramedullary disease in patients with multiple myeloma in the era of novel therapy and the activity of pomalidomide in extramedullary myeloma. *Leukemia.* 2011;**25**:906–8.
- Weinstock M, Aljawai Y, Morgan EA, Laubach J, Gannon M, Roccaro AM, et al. Incidence and clinical features of extramedullary multiple myeloma in patients who underwent stem cell transplantation. *Br J Haematol.* 2015;**169**:851–8.
- Papanikolaou X, Repousis P, Tzenou T, Maltezas D, Kotsopoulou M, Megalaki K, et al. Incidence, clinical features, laboratory findings and outcome of patients with multiple myeloma presenting with extramedullary relapse. *Leuk Lymphoma.* 2013;**54**:1459–64.
- Touzeau C, Moreau P. How I treat extramedullary myeloma. *Blood.* 2016;**127**:971–6.
- Usmani SZ, Mitchell A, Waheed S, Crowley J, Hoering A, Petty N, et al. Prognostic implications of serial 18-fluoro-deoxyglucose emission tomography in multiple myeloma treated with total therapy 3. *Blood.* 2013;**121**:1819–23.
- Caers J, Paiva B, Zamagni E, Leleu X, Bladé J, Kristinsson SY, et al. Diagnosis, treatment and response assessment in solitary plasmacytoma: updated recommendations from a European Expert Panel. *J Hematol Oncol.* 2018;**11**:1–10.
- Churg J, Gordon AJ. Multiple myeloma: lesions of the extra-osseous hematopoietic system. *Am J Clin Pathol.* 1950;**20**:934–45.
- Hayes DW, Bennett WA, Heck FJ. Extramedullary lesions in multiple myeloma: review of the literature and pathologic studies. *AMA Arch Pathol.* 1952;**53**:262–72.
- Pasmantier MW, Azar HA. Extraskelatal spread in multiple plasma cell myeloma: a review of 57 autopsied cases. *Cancer.* 1969;**23**:167–74.
- Bartel B, Haessler J, Brown TLY, Shaughnessy JD, van Rhee F, Anaissie E, et al. F18-fluorodeoxyglucose positron emission tomography in the context of other imaging techniques and prognostic factors in multiple myeloma. *Blood.* 2009;**114**:2068–76.
- Zamagni E, Patriarca F, Nanni C, Zannetti B, Englaro E, Pezzi A, et al. Prognostic relevance of 18-F FDG PET/CT in newly diagnosed multiple myeloma patients treated with up-front autologous transplantation. *Blood.* 2011;**118**:5989–95.
- Moreau P, Attal M, Caillot D, Macro M, Karlin L, Garderet L, et al. Prospective evaluation of magnetic resonance imaging and [18F]Fluorodeoxyglucose positron emission tomography-computed tomography at diagnosis and before maintenance therapy in symptomatic patients with multiple myeloma included in the IFM/DFCI 2009 trial: results of the IMAJEM study. *J Clin Oncol.* 2017;**35**:2911–8.
- Fernández de Larrea C, Jiménez R, Rosiñol L, Giné E, Tovar N, Cibeira MT, et al. Pattern of relapse and progression after autologous stem cell transplantation as upfront therapy in multiple myeloma. *Bone Marrow Transplant.* 2014;**49**:223–7.
- Pérez-Simón JA, Sureda A, Fernández-Avilés F, Sampol A, Cabrera JR, Caballero D, et al. Reduced-intensity conditioning allogeneic transplantation is associated with a high incidence of extramedullary relapses in multiple myeloma patients. *Leukemia.* 2006;**20**:542–5.
- Minnema MC, van de Donk NW, Zweegman S, Hegenbart U, Schonland S, Raymakers R, et al. Extramedullary relapses after allogeneic non-myeloablative stem cell transplantation in multiple myeloma patients do not negatively affect treatment outcome. *Bone Marrow Transplant.* 2004;**34**:1057–65.
- Zeiser R, Deschler B, Bertz H, Finke J, Engelhardt M. Extramedullary vs medullary relapse after autologous or allogeneic hematopoietic stem cell transplantation (HSCT) in multiple myeloma (MM) and its correlation to clinical outcome. *Bone Marrow Transplant.* 2004;**34**:1057–65.
- Alegre A, Granda A, Martínez-Chamorro C, Díaz-Mediavilla J, Martínez R, García-Larana J, et al. Different patterns of relapse after autologous peripheral blood stem cell transplantation in multiple myeloma: clinical results of 280 cases from the Spanish Registry. *Haematologica.* 2002;**87**:609–14.
- Lenhoff S, Hjorth M, Turesson I, Westin J, Gimsing P, Wisloff F, et al. Intensive therapy for multiple myeloma in patients younger than 60 years: long-term results focusing on the effect of the degree of response

- on survival and relapse pattern after transplantation. *Haematologica*. 2006;**91**:1228–33.
32. Vincent L, Ceballos P, Plassot C, Ménié JC, Quittet P, Navarro R, et al. Factors influencing extramedullary relapse after allogeneic transplantation for multiple myeloma. *Blood Cancer J*. 2015;**5**:e341.
  33. Rosiñol L, Jiménez-Segura R, Cibeira MT, Fernández de Larrea C, Bladé E, Tovar N, et al. Plasmacytomas in multiple myeloma: 45-years experience from a single institution. *Clin Lymphoma Myeloma Leuk*. 2017;**17**:e107.
  34. Moreau P, Polliack A. Extramedullary multiple myeloma: extraosseous relapse is extra “bad news”, but why? *Leuk Lymphoma*. 2013;**54**:1349–50.
  35. Bladé J, Fernández de Larrea C, Rosiñol L. Extramedullary disease in multiple myeloma in the era of novel agents. *Br J Haematol*. 2015;**169**:763–5.
  36. Jurczynsyn A, Olszewska-Szopa M, Hungria V, Crusoe E, Pika T, Delforge M, et al. Cutaneous involvement in multiple myeloma: a multi-institutional retrospective study of 53 patients. *Leuk Lymphoma*. 2016;**57**:2071–6.
  37. Fassas AB, Ward S, Muwalla F, Van Hemert R, Schluterman K, Harik S, et al. Myeloma of the central nervous system: strong association with unfavourable chromosomal abnormalities and other high-risk disease features. *Leuk Lymphoma*. 2004;**45**:291–300.
  38. Nieuwenhuizen L, Biesma DH. Central nervous system myelomatosis: review of the literature. *Eur J Haematol*. 2007;**80**:1–9.
  39. Schluterman KO, Fassas AB, Van Hemert RL, Harik SI. Multiple myeloma invasion of the central nervous system. *Arch Neurol*. 2004;**61**:1423–9.
  40. Chamberlain MC, Glanz M. Myelomatous meningitis. *Cancer*. 2008;**112**:1562–7.
  41. Gozzetti A, Cesare A, Lotti F, Rossi D, Palumbo A, Petrucci MT, et al. Extramedullary intracranial localization of multiple myeloma and treatment with novel agents: a retrospective survey of 50 patients. *Cancer*. 2012;**118**:1574–84.
  42. Jurczynsyn A, Grzasko N, Gozzetti A, Czepiel J, Cerase A, Hungria V, et al. Central nervous system involvement by multiple myeloma: a multi-institutional retrospective study of 172 patients in daily clinical practice. *Am J Hematol*. 2016;**91**:575–80.
  43. Chen CI, Masih-Khan E, Jiang H, Rabea A, Cserti-Gazdewich C, Jimenez-Zepeda VH, et al. Central nervous system involvement in multiple myeloma: long-term survival can be achieved with radiation, intrathecal chemotherapy and immunomodulatory agents. *Br J Haematol*. 2013;**162**:483–8.
  44. Reseblum MD, Bredeson CN, Chang CC, Rizzo JD. Subcutaneous plasmacytomas with tropism to sites of previous trauma in a multiple myeloma patient treated with an autologous bone marrow transplant. *Am J Hematol*. 2003;**72**:274–7.
  45. Fernández de Larrea C, Rosiñol L, Cibeira MT, Rozman M, Rovira M, Bladé J. Extensive soft-tissue involvement by plasmablastic myeloma arising from displaced humeral fractures. *Eur J Haematol*. 2010;**85**:448–51.
  46. Moreno D, Setoain X, Bladé J, Rosiñol L. Extramedullary plasmacytoma over the scar from long-lasting past surgery as presenting feature of multiple myeloma. *Arch Clin Biomed Res*. 2020;**4**:766–74.
  47. Rosiñol L, Fernández de Larrea C, Bladé J. Extramedullary myeloma spread triggered by surgical procedures: an emerging entity? *Acta Haematol*. 2014;**132**:36–8.
  48. Yata K, Yaccoby S. The SCID-rab model: a novel in vitro system for primary human myeloma demonstrating growth of CD138-expressing malignant cells. *Leukemia*. 2004;**18**:1891–7.
  49. Katodritou E, Gastari V, Verrou E, Hadjiaggelidou C, Varthaliti M, Georgiadou S, et al. Extramedullary (EMP) relapse in unusual locations in multiple myeloma: is there an association with precedent thalidomide administration and a correlation of special biological features with treatment and outcome? *Leuk Res*. 2009;**33**:1137–40.
  50. Cerny J, Fadare O, Li H, Wang SA. Clinicopathological features of extramedullary recurrence/relapse of multiple myeloma. *Eur J Haematol*. 2008;**81**:65–9.
  51. Pellat-Deceunynck C, Barillé S, Jego G, Puthier D, Robillard N, Pineau D, et al. The absence of CD56 (NCAM) on malignant plasma cells is a hallmark of plasma cell leukemia and of a special subset of multiple myeloma. *Leukemia*. 1998;**12**:1977–82.
  52. Chang H, Barlett E, Patterson B, Chen I, Yi QL. The absence of CD56 on malignant plasma cells in the cerebrospinal fluid is the hallmark of multiple myeloma involving central nervous system. *Br J Haematol*. 2005;**129**:539–41.
  53. Sheth N, Yeung J, Chang H. P53 nuclear accumulation is associated with extramedullary progression on multiple myeloma. *Leuk Res*. 2009;**33**:1357–60.
  54. Chang H, Sloan S, Li D, Stewart K. Multiple myeloma involving central nervous system: high frequency of chromosome 17p13 (p53) deletions. *Br J Haematol*. 2014;**127**:280–4.
  55. López-Anglada L, Gutiérrez NC, García JL, Mateos MV, Flores T, San Miguel JF. P53 deletion may drive the clinical evolution and treatment response in multiple myeloma. *Eur J Haematol*. 2010;**84**:359–61.
  56. Besse L, Sedlarikova L, Greslikova H, Kupsta R, Almasi M, Penka M, et al. Cytogenetics in multiple myeloma patients progressing into extramedullary disease. *Eur J Haematol*. 2016;**97**:93–100.
  57. Billecke L, Murga Penas EM, May AM, Engelhardt M, Nagler A, Leiba M, et al. Similar incidence of TP53 deletions in extramedullary organ infiltrations, soft tissue and osteolysis of patients with multiple myeloma. *Anticancer Res*. 2012;**32**:2031–4.
  58. Billecke L, Murga Penas EM, May AM, Engelhardt M, Nagler A, Leiba M, et al. Cytogenetics of extramedullary manifestations in multiple myeloma. *Br J Haematol*. 2013;**161**:87–94.
  59. Deng S, Xu Y, An G, Sui W, Zou D, Zhao Y, et al. Features of extramedullary disease of multiple myeloma: high frequency of p53 deletion and poor survival: a retrospective single center study of 834 cases. *Clin Lymphoma Myeloma Leuk*. 2015;**15**:286–91.
  60. Rasche L, Bernard C, Topp MS, Kapp M, Duell J, Wesemeier C, et al. Features of extramedullary myeloma relapse: high proliferation, minimal marrow involvement, adverse cytogenetics: a retrospective single-center study of 24 cases. *Ann Hematol*. 2012;**91**:1031–7.
  61. Rosiñol L, Oriol A, Teruel AI, Hernández D, López-Jiménez J, de la Rubia J, et al. Superiority of bortezomib, thalidomide and dexamethasone (VTD) as induction pre-transplantation therapy in multiple myeloma: results of a randomized phase III PETHEMA/GEM study. *Blood*. 2012;**120**:1589–96.
  62. Dimopoulos MA, Terpos E, Comenzo RL, Tosi P, Beksac M, Sezer O, et al. International Myeloma Working Group consensus statement and guidelines regarding the current role of imaging techniques in the diagnosis and monitoring of multiple myeloma. *Leukemia*. 2009;**23**:1545–56.
  63. Dimopoulos MA, Kyle RA, Fermand JP, Rajkumar SV, San Miguel J, Chanan-Khan A, et al. Consensus recommendations for standard investigative workup: report on the International Myeloma Workshop Consensus Panel 3. *Blood*. 2011;**117**:4701–5.
  64. Dimopoulos MA, Hillengass J, Usmani S, Zamagni E, Lentzsch S, Davies FE, et al. Role of magnetic resonance imaging in the management of multiple myeloma: a consensus statement. *J Clin Oncol*. 2015;**33**:657–64.
  65. Zamagni E, Cavo M. The role of imaging techniques in the management of multiple myeloma. *Br J Haematol*. 2012;**159**:499–513.
  66. Zamagni E, Nanni C, Tachetti P, Pantani L, Marzocchi G, Zannetti B, et al. Positron emission tomography with computed tomography-based diagnosis of massive extramedullary progression in a patient with high-risk multiple myeloma. *Clin Lymphoma Myeloma Leuk*. 2014;**14**:e101–4.
  67. Nanni C, Zamagni E, Versari A, Chauvie S, Bianchi A, Rensi M, et al. Image interpretation criteria for FDG PET/CT in multiple myeloma: a new proposal from an Italian expert panel. IMPeTUs (Italian Myeloma criteria for PET Use). *Eur J Nucl Med Mol Imaging*. 2016;**43**:414–21.
  68. Lu YY, Chen JH, Lin WY, Liang JA, Wang HY, Tsai SC, et al. FDG-PET or PET/CT for detecting intramedullary and extramedullary lesions in multiple myeloma: a systematic review and metaanalysis. *Clin Nucl Med*. 2012;**37**:833–7.



- myeloma without intent for immediate autologous stem-cell transplant (SWOG SO777): a randomised, open-label, phase 3 trial. *Lancet*. 2017;**389**:519–27.
101. Sonneveld P, Goldschmidt H, Rosiñol L, et al. Bortezomib-based versus non-bortezomib-based induction treatment before autologous stem-cell transplantation in patients with previously untreated multiple myeloma: a meta-analysis of phase III randomized, controlled trials. *J Clin Oncol*. 2013;**31**:3279–87.
  102. San Miguel JF, Schlag R, Khuageva NK, Dimopoulos MA, Shpilberg O, Kropff M, et al. Bortezomib plus melphalan and prednisone for initial treatment of multiple myeloma. *N Engl J Med*. 2008;**359**:906–17.
  103. Barlogie B, Anaissie E, van Rhee F, Pineda-Roman M, Zangari M, Shaughnessy J, et al. The Arkansas approach to therapy in patients with multiple myeloma. *Best Pract Res*. 2007;**20**:761–81.
  104. Rosiñol L, Jiménez R, Rovira M, Martínez C, Fernández-Aviles F, Marin P, et al. Allogeneic hematopoietic SCT in multiple myeloma: long-term results from a single institution. *Bone Marrow Transplant*. 2015;**15**:658–62.
  105. Moreau P, Cavo M, Sonneveld P, Rosinol L, Attal M, Pezzi A, et al. Combination of international scoring system 3, high lactate dehydrogenase, and t(4;14) and/or del(17p) identifies patients with multiple myeloma (MM) treated with front-line autologous stem-cell transplantation at high risk of early MM progression-related death. *J Clin Oncol*. 2014;**32**:2173–80.
  106. Cavo M, Golschmidt H, Rosiñol L, Pantani L, Zweegman S, Salwender HJ, et al. Double vs single autologous stem cell transplantation for newly diagnosed multiple myeloma: long-term follow-up (10-years) analysis of randomized Phase 3 studies. *Blood*. 2018;**132**(Suppl 1):124.
  107. Srikanth M, Davies FE, Wu P, Jenner MW, Ethell ME, Potter MN, et al. Survival and outcome of blastoid variant myeloma following treatment with the novel thalidomide containing regimen DT-PACE. *Eur J Haematol*. 2008;**81**:432–6.
  108. Rasche L, Striffler S, Duell J, Rosenwald A, Buck A, Maeder U, et al. The lymphoma-like polychemotherapy regimen “Dexa-BEAM” in advanced and extramedullary multiple myeloma. *Ann Hematol*. 2014;**93**:1207–14.
  109. Isola I, Granell M, Martí Josep M, Gironella M, García-Guínón A, López-Pardo J, et al. PACE como tratamiento de rescate en pacientes con mieloma múltiple recaído o refractario. *Haematologica* 2015;**100**:S4. 46# abstract CO-070.
  110. Rodríguez-Lobato LG, Ganzetti M, Fernández de Larrea C, Hudecek M, Einsele H, Danhof S. CAR T-cells in multiple myeloma: state of the art and future directions. *Front Oncol*. 2020;**10**:1243.
  111. Lonial S, Lee HC, Badros A, Trudel S, Nooka AK, Chari A, et al. Belantamab mafodotin for relapsed or refractory multiple myeloma (DREAMM-2): a two-arm, randomised, open-label, phase 2 study. *Lancet Oncol*. 2020;**21**:207–21.
  112. Smith EL, Mailankody S, Staehr M, Wang X, Senechal B, Purdon TJ, et al. BCMA-targeted CAR-T cell therapy plus radiotherapy for the treatment of refractory myeloma reveals potential synergy. *Cancer Immunol Res*. 2019;**7**:1047–53.
  113. Brudno JN, Maric I, Hartman SD, Rose JJ, Wang M, Lam N, et al. T cells genetically modified to express an anti-B-cell maturation antigen chimeric antigen receptor cause remissions of poor prognosis in relapsed multiple myeloma. *J Clin Oncol*. 2018;**36**:2267–80.
  114. Raje N, Berdeja J, Lin Y, Siegel D, Jagannath S, Madduri D, et al. Anti-BCMA CAR-T cell therapy bb2121 in relapsed or refractory multiple myeloma. *N Engl J Med*. 2019;**380**:1726–37.
  115. Cohen AD, Garfall AL, Stadtmauer EA, Melenhorst JJ, Lacey SF, Lancaster E, et al. B cell maturation antigen-specific CAR-T cells are clinically active in multiple myeloma. *J Clin Invest*. 2019;**129**:2210–21.